

Original Paper

Retracted: Application of Robot Positioning for Cannulated Screw Internal Fixation in the Treatment of Femoral Neck Fracture: Retrospective Study

Lei Wan, MD; Xiangyun Zhang, MD; Dalong Wu, MD; Zhihao Li, MD; Dongtao Yuan, MD; Junming Li, MD; Shikui Zhang, MD; Long Yue, MD; Shao'an Zhang, MD

Department of Osteology, The Second Affiliated Hospital of Luohe Medical College, Luohe, China

Corresponding Author:

Shao'an Zhang, MD
Department of Osteology
The Second Affiliated Hospital of Luohe Medical College
463 Haihe Road
Luohe, 462300
China
Phone: 86 13938012488
Email: 13938012488@163.com

Related Article:

Do not cite this article - this article has been retracted. Retraction notice: <https://medinform.jmir.org/2026/1/e102057/>

Abstract

Background: Femoral neck fracture is a common type of hip fracture. Conventional surgical treatment aims at fixing the fracture site with screws and then gradually promoting bone healing. A robot-assisted orthopedic surgery system is computer technology applied to surgical treatment.

Objective: This study aimed to explore the therapeutic effect and prognostic value of percutaneous cannulated screw internal fixation using robot-assisted positioning in patients with femoral neck fractures.

Methods: From July 2018 to September 2019, 42 cases of femoral neck fracture admitted to the Second Affiliated Hospital of Luohe Medical College were randomly and averagely divided into control and study groups. The patients in the control group were treated with conventional percutaneous cannulated screw internal fixation, while the patients in the study group were treated with robot-assisted percutaneous cannulated screw fixation during surgical treatment. We compared the treatment conditions and results of the operation between the 2 groups. The Harris score was used to evaluate the treatment efficacy. The state of fracture healing was followed up and compared between the 2 groups.

Results: The duration of the operation was shorter, there was less fluoroscopy use, and there were fewer drilled holes in the study group than in the control group (all, $P < .001$). There was no statistical difference in the amount of intraoperative bleeding between the 2 groups ($P = .33$). The Harris score ($P = .045$) and number of excellent and good ratings ($P = .01$) were significantly higher in the study group than in the control group. The difference in the fracture healing rate between the 2 groups was not statistically significant ($P = .23$). The fracture healing duration of the study group was shorter than that of the control group ($P = .001$).

Conclusions: The use of robotic positioning aids in the treatment of femoral neck fractures with percutaneous cannulated screw fixation can effectively improve the efficiency of surgery, shorten the duration of surgery, and reduce the radiation damage to patients. Meanwhile, it improves postoperative treatment and recovery rates of the patients and shortens the fracture healing time.

(*JMIR Med Inform* 2021;9(1):e24164) doi: [10.2196/24164](https://doi.org/10.2196/24164)

KEYWORDS

percutaneous cannulated screw fixation; robot positioning; femoral neck fracture; clinical efficacy; prognosis

Introduction

Femoral neck fracture is a common type of hip fracture. Due to the special location of the fracture, the incidence of femoral neck fracture necrosis is high, and the prognosis is poor, which seriously affects the patient's activities of daily life [1]. For elderly patients, conventional treatment is often used in clinical practice. With the continuous development of surgical techniques and surgical instruments, screw placement and internal fixation use in femoral neck fractures are gradually increasing [2]. Conventional surgical treatment aims at fixing the fracture site with screws and gradually promoting bone healing. The fixation of the screws and precise positioning of the screws in the operating room are difficult. The quality of screw positioning and fixation is closely related to the prognosis of the patient. Fixation effect is the focus of current clinical research [3].

With improvement in medical technology and the rapid development of minimally invasive surgery, surgical robots were introduced in the 1980s and first used in brain surgery in 1985 [4]. With the advantages of good stability, flexible operation, accurate movement, and hand-eye coordination, surgical robots are increasingly used in clinical treatment including orthopedic surgery. According to the requirements of precision medicine, navigation-assisted technology has been widely used in orthopedic surgery because of the safety, accuracy, and rapidity in orthopedic surgery [5]. Navigation assistance technology was introduced in the 1980s as one of the core technologies of orthopedic robots, which can provide an accurate reference for the robot operation using the computer data processing functionality, analyzing and processing patient image data obtained from X-ray, computed tomography (CT), and other imaging equipment, so as to provide surgery planning for doctors [6-8]. At the same time, it can track external space coordinates. In order to obtain the relative position relationship between the surgical target area and surgical instruments or robots, we can guide doctors to accurately, quickly, and safely locate and implant implants [9].

A robot-assisted orthopedic surgery system is computer technology applied to surgical treatment. It can process the patient's imaging information through computer algorithms to help doctors determine the appropriate treatment model and assist in surgical treatment [10]. The purpose of this study was to explore the therapeutic effect and prognostic value of the application of robot-assisted positioning in percutaneous cannulated screw internal fixation in patients with femoral neck fractures through comparative analysis.

Methods

Data Source

From July 2018 to September 2019, 42 patients with femoral neck fractures admitted to the Second Affiliated Hospital of Luohe Medical College were included. Femoral neck fractures were mainly defined by imaging examination including X-ray, CT, and magnetic resonance imaging. At present, the Garden classification is the most commonly used classification standard and can be divided into 4 types according to the degree of

fracture displacement [11]. In this study, the inclusion criteria were as follows: (1) met the diagnostic criteria of femoral neck fracture, with the fracture classification determined by X-ray examination; (2) complete clinical data and first diagnosis in our hospital; and (3) written informed consent. The exclusion criteria were as follows: (1) unable to undergo surgical treatment, such as age >65 years with a Garden classification of type III or IV, not fixed with 3 cannulated screws, poor reduction, hip joint anteroposterior and lateral X-ray films with fracture block displacement <3 mm, pathological fractures; (2) severe liver, kidney, or cardiovascular disease; (3) multiple trauma or fractures in other parts of the body; and (4) difficulty with follow-up or unable to follow-up.

All patients were randomly divided into 2 groups (control group and study group), with 21 patients in each group. Oral consent was obtained from patients. Basic clinical data and clinical data were obtained from electronic medical records. Electronic medical information included demographic data, general surgical conditions, and state of fracture healing.

First, we compared the general surgical conditions between the 2 groups, including the duration of operation, frequency of intraoperative fluoroscopy usage, amount of intraoperative blood loss, and number of intraoperative holes. Second, the number of excellent ratings of the treatment was compared between the 2 groups. We used the Harris score [12] to evaluate the treatment of the 2 groups, including hip joint function, pain, deformity, and joint mobility: excellent (90-100 points), good (80-89 points), medium (70-79 points), and poor (<70 points). Finally, the status of fracture healing was compared between the 2 groups. Meanwhile, healing progress of both groups was followed up and monitored, and we recorded the number of healings and the average healing time of the recovering patients.

Methods and Materials

The patients in the control group were treated using a traditional reduction operation with percutaneous cannulated screw internal fixation. The patients were placed in a supine position and anesthetized in the subarachnoid space. After completing anatomical reduction of the fracture site under C-arm fluoroscopy, 3 Kirschner wires were used to treat the patients. C-arm fluoroscopy was used again to monitor the lateral position of the hip joint, as well as the placement and depth of the Kirschner wires. If there was an abnormality in the position of the Kirschner wires, they were pulled out for repositioning. The needle tip position was kept 0.5 mm below the cartilage of the femoral head. After the position was considered satisfactory, the length of the Kirschner wires was measured. This was followed by inserting the cannulated screws in sequence, according to the position and depth of the Kirschner wires. Finally, C-arm fluoroscopy was used again to confirm whether the cannulated screw was successfully implanted. If successful, the wound was sutured.

The patients in the study group were treated using the TIANJI robotic positioning system for orthopedic surgery (Catalog, HY001512, TINAVI Medical Technologies Co. Ltd, Beijing, China) as adjuvant therapy in conventional surgical procedures, which is the third generation of the TIANJI orthopedic robot. At first, a treatment model of femoral neck fracture was

established. After completing the anatomical reduction, the robot was placed in a suitable position, and the preliminary positioning was completed. Then, the robot was covered with a sterile plastic film and placed in the preliminary marked position, the accuracy of which was determined and fixed. A C-arm X-ray monitor was placed at the lateral hip side. Based on the collected patient data, follow-up surgical planning was made. After all plans and preparation were completed, 3 hollow screws were inserted according to standards. The entire length of the hollow screws was calculated, and the mechanical arm of the robot started to position and navigate the screw. After the position was confirmed, the hollow screw was inserted. Finally, C-arm fluoroscopy was used again to confirm the location, and the wound was sutured after confirmation. Both groups of patients underwent routine anti-infective treatment, with the follow-up time set at 6 months.

Statistical Analysis

SPSS 25.0 software was used for statistical analysis of the data. The categorical variables are presented as frequencies and percentages. Continuous variables are described using mean and SD. We used *t* tests when the data were normally distributed (Shapiro-Wilk test). A chi-squared test or Fisher exact test was performed to compare the proportions of categorical variables. A 2-sided α was considered statistically significant when less than .05.

Results

Comparison of the General Characteristics of Patients Between the Groups

In the control group, the patient age range was 29-67 years, and the mean (SD) age was 51.33 years (4.30 years). The disease course was 3-17 days, and the mean (SD) disease course was 6.83 days (3.91 days). There were 14 men and 7 women. The causes of injury were described as the following: 10 cases of car accidents, 6 cases of falls, and 5 cases of sports. There were 4 Garden II cases, 12 Garden III cases, and 5 Garden IV cases according to the Garden classification.

In the study group, patients were 31-68 years old, with a mean (SD) age of 51.86 years (4.89 years). The clinical course of disease was 2-19 days, with a mean (SD) course of 6.67 days (3.68 days). There were 12 male patients and 9 female patients. The causes of injury were stated as the following: 9 cases of car accidents, 8 cases of falls, and 4 cases of sports. There were 5 Garden II cases, 13 Garden III cases, and 3 Garden IV cases according to the Garden classification. The general difference in the clinical data between these 2 groups was not statistically significant ($P>.05$).

Comparison of the General Surgical Characteristics of the Operation Between the Groups

The duration of surgery was shorter, there was less use of intraoperative fluoroscopy, and there were fewer drilled holes in the study group than in the control group (all, $P<.001$). The difference in the amount of intraoperative bleeding between the 2 groups was not statistically significant ($P=.33$). Details can be seen in [Table 1](#).

Table 1. Comparison of the general surgical characteristics of the operation between the 2 groups of patients.

Characteristics	Control group (n=21)	Study group (n=21)	<i>t</i> test ^a	<i>P</i> value
Operation duration (minutes), mean (SD)	88.29 (14.29)	64.12 (10.86)	6.171	<.001
Frequency of intraoperative fluoroscopy, n	19.86 (3.29)	12.20 (2.11)	9.098	<.001
Intraoperative blood loss (mL), mean (SD)	76.92 (8.29)	74.51 (7.48)	0.989	.33
Frequency of intraoperative drilling, n	10.71 (2.92)	5.52 (1.43)	7.315	<.001

^adegrees of freedom: 40.

Comparison of the Excellent and Good Ratings of Treatment Between the Groups

The Harris score of the study group was significantly higher than that of the control group ($P=.045$), and 19 of the 21 patients

(90%) in the study group had excellent or good ratings, which was significantly higher than the number in the control group (12/21, 57%; $P=.014$). Details can be seen in [Table 2](#).

Table 2. Comparison of the excellent and good ratings of the treatment between the 2 groups of patients.

Ratings	Control group (n=21)	Study group (n=21)	Comparison	P value
Harris score, mean (SD)	88.86 (9.24)	94.24 (7.52)	$t_{40}=2.060$.045
Excellent, n (%)	4 (19)	13 (62)	$\chi_1=8.005$.005
Good, n (%)	8 (38)	6 (29)	$\chi_1=0.429$.51
Average, n (%)	7 (33)	2 (10)	$\chi_1=2.263$.13
Poor, n (%)	2 (10)	0 (0)	$\chi_1=0.525$.47
Excellent and good, n (%)	12 (57)	19 (90)	$\chi_1=6.035$.01

Comparison of the Fracture Healing Rates Between the Groups

The fracture healing rate in the study group was 100% (21/21), and in the control group, it was 86% (18/21); the difference was not statistically significant ($P=.23$). There was no internal

fixation loosening, fracture displacement or necrosis, infection, or other complication in the study group. However, 3 patients in the control group had internal fixation loosening. Finally, the fracture healing time of the study group was significantly shorter than that of the control group ($P=.001$; [Table 3](#)).

Table 3. Comparison of fracture healing rates between the 2 groups of patients.

Fracture healing	Control group (n=21)	Study group (n=21)	Comparison	P value
Healed cases, n (%)	18 (86)	21 (100)	$\chi_1=1.436$.23
Healing duration (months), mean (SD)	4.45 (0.48)	3.98 (0.33)	$t_{40}=3.605$.001

Typical Cases

There was a 49-year-old male patient in the study group with a fracture of the right femoral neck. He was treated with robot-assisted percutaneous cannulated screw internal fixation. Before the surgery, the treatment model for the femoral neck fracture was established. After anatomical reduction, the robot was placed in a suitable position to complete the preliminary positioning. The C-arm X-ray machine was used to obtain the intraoperative fluoroscopy image containing the robot positioning mark points and transmit it to the host workstation for registration calculation. According to the images collected during the operation, the screw path planning was carried out in the master control system planning software based on the typical marking points and bony landmarks. The path of the femoral neck screw channel was confirmed by anteroposterior and lateral biplane images, which are displayed in [Figure 1A](#) and [Figure 1B](#). The safety of operation and best mechanical distribution of the screws should be considered when designing the operation. The bony boundary between the upper cortex of the femoral neck and under the femoral moment and the

relationship between the screw and fracture line were confirmed by the anteroposterior image of the femoral neck screw. The relationship between the internal and external boundary of the femoral neck bone cortex and the relationship between the screw and femoral neck anteversion were confirmed on the femoral neck screw lateral image, and the screw length was adjusted according to the apex distance. After confirming the accurate path, the guide needle was drilled into the bony channel through the sleeve under fluoroscopy monitoring ([Figure 1C](#)). After confirming the position of the guide pin through fluoroscopy, hollow screws were used for internal fixation ([Figure 1D](#)). After the operation, X-ray observation was performed on the fixation ([Figure 2B](#)). The lateral image, as shown in [Figure 1A](#) and [Figure 1D](#), was compared between the postoperative fluoroscopic anteroposterior view and preoperative planning of the surgical path, which showed that there was no deviation from the planned path. The comparison between the preoperative robot planning and postoperative perspective positive position comparison is shown in [Figure 1A](#) and [Figure 1D](#). After the operation, the typical patient healed in 3 months.

Figure 1. Application of robot positioning for cannulated screw internal fixation in the treatment of femoral neck fracture, with preoperative planning by the orthopedic surgery robot for the (A) anteroposterior femoral neck and (B) lateral femoral neck view. (C) Intraoperative fluoroscopy-assisted guiding of the needles and (D) postoperative radiograph after cannulated screw femoral fixation.

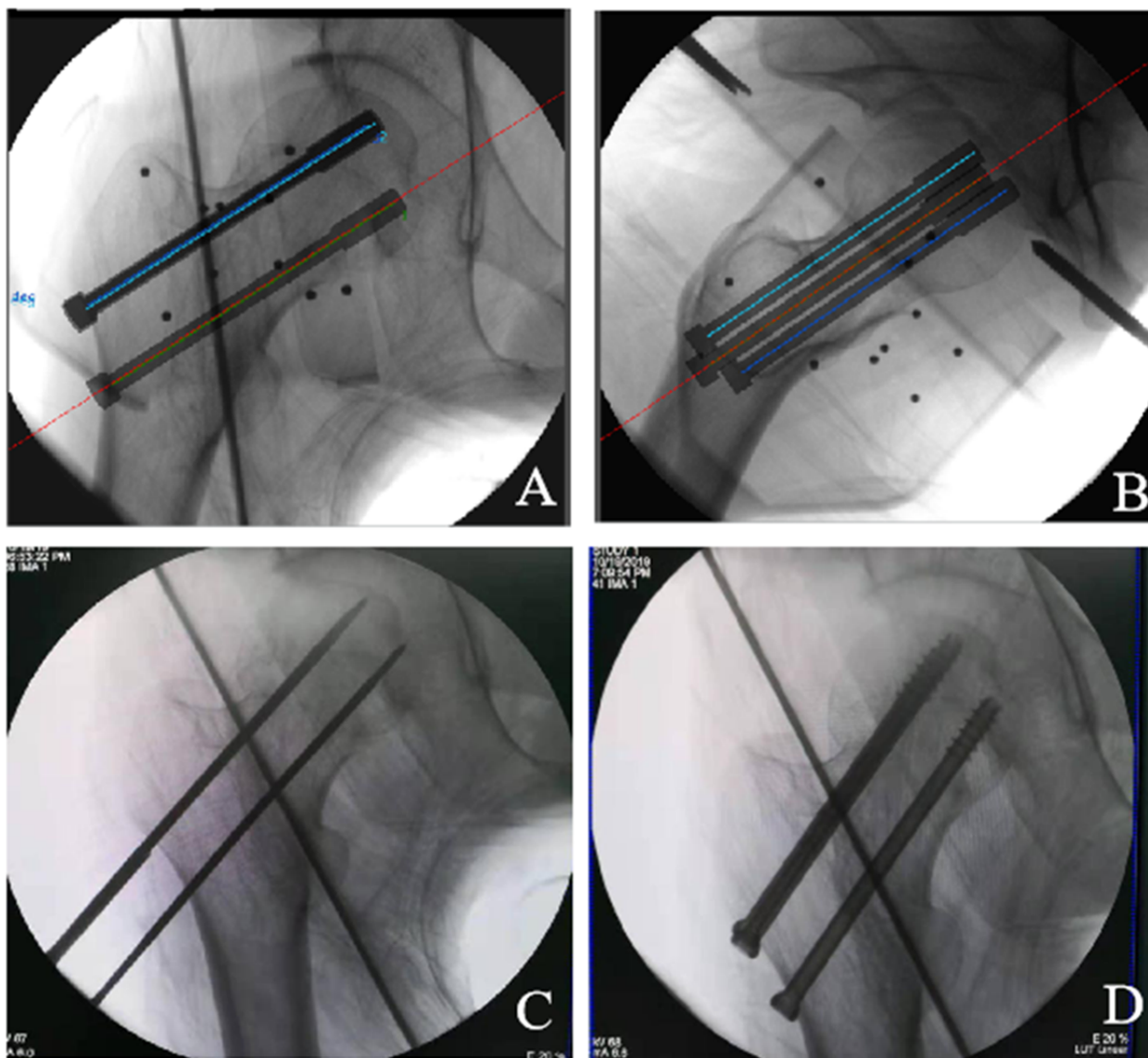
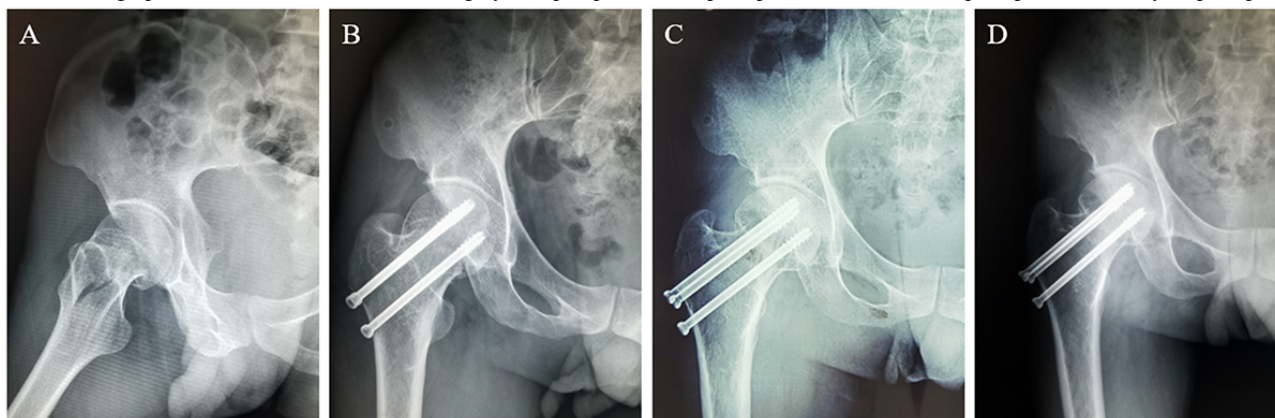


Figure 2. Radiograph of the femoral neck after the surgery: (A) preoperative (B) postoperative, (C) 3 months postoperative, (D) 1 year postoperative.



Discussion

In the surgical treatment of femoral neck fractures, to ensure the success of the anatomical reduction of the fracture site, the key is using cannulated screws for internal fixation, which is currently followed in clinical practice. Choosing the appropriate implantation site and implantation depth are the key considerations during the procedure [13-15]. In conventional surgery, C-arm fluoroscopy is used to observe the patient's fracture reduction and make adjustments whenever necessary. Due to human vision and operation errors, it is often necessary to adjust the patient multiple times, which affects the outcome of the surgery [16,17]. With the continuous development of computer technology, robot-assisted positioning treatment has been widely used in surgical operations. By integrating patient imaging data, the robot can establish a more reasonable treatment model and navigate clinical operations to improve the accuracy of surgical treatment [18]. The purpose of this study was to explore the therapeutic effect and prognostic value of the application of robotic positioning in patients with femoral neck fractures during percutaneous cannulated screw internal fixation through comparative analysis.

Principal Findings

The results showed that the study group had shorter surgery lengths, less use of intraoperative fluoroscopy, and fewer drilled holes than the control group (all, $P < .001$). The robot-assisted internal fixation surgery was more efficient, was safer, and had less radiation damage to the patients. As an orthopedic surgery robot is a computer-assisted system designed with capabilities to carry out orthopedic surgery, it can accurately analyze patient's imaging data and establish a corresponding treatment model and surgical requirements according to the characteristics of the femoral neck fractures, according to the fracture situation and femoral data of the different patients. When the surgeon implants the cannulated screws, he or she can perform surgical treatment according to the optimal model designed by the robot [19,20], avoiding position deviation caused by the inevitable hand instability during the operation and reducing the necessity for redrilling and replanting. It also reduces the risk of extra fluoroscopy exposure for the patient, reduces radiation damage to the human body, and improves the safety of surgery.

The Harris score of the study group was significantly higher than that of the control group ($P < .05$), and the number of patients in the study group with an excellent or good rating

(19/21, 90%) was significantly higher than in the control group ($P < .05$). In the evaluation of the surgical effect after the surgery, patients with robot-assisted treatment also showed obvious advantages. Conventional surgery inevitably produces errors due to human visual judgment, and it is difficult to guarantee the absolute accuracy of screw implantation [21,22]. Through robot-assisted surgery, the effect of screw implantation may be significantly improved, remarkably improving the patient's postoperative recovery of hip joint function. The surgical effect may be significantly improved, and postoperative pain caused by inadequate surgical treatment may be reduced. Postoperative deformity and other complications may also be largely avoided.

At the same time, the follow-up results showed that the rate of fracture healing in the study group (21/21, 100%) was slightly higher than that in the control group. There were no complications such as loosening of internal fixation, fracture displacement, necrosis, or infection in the study group. The fracture healing time of the study group was significantly shorter than that in the control group ($P < .05$). In conventional treatment, the recovery of femoral neck fractures cannot reach completely ideal conditions. Some patients are prone to serious complications such as femoral head necrosis due to anatomical reduction, and serious cases may lead to the death of patients [22-24]. The robot-assisted system has ideal performance in the treatment of femoral neck fractures. While surgery requires high reduction, the robot-assisted system can provide accurate navigation capabilities, so that patients can avoid secondary needle placement during surgery. Safety and accuracy of surgical operations are significantly improved, while the radiation-related damage to the body is reduced, improving the natural recovery ability of the human body, so that the recovery time of the patient is shortened and the recovery rate is significantly improved.

Conclusions

In summary, the use of orthopedic surgical robots for auxiliary treatment of femoral neck fractures with percutaneous cannulated screw fixation can effectively improve the efficiency of drilling and fixation, help to shorten the duration of surgery, reduce radiation damage to patients, and improve the safety of surgery. The femoral reduction effect is significantly improved, and patients achieve more remarkable treatment outcomes. At the same time, the use of robot-assisted surgery can shorten the recovery time of patients after surgery, improve the healing rate of fractures, and improve patients' prognosis.

Acknowledgments

This study was supported by the Project of Top Youth Talents of Luohe (grant number LBJZ210602).

Authors' Contributions

ZS conducted the study, had full access to all the data, and takes responsibility for the integrity of the data and the accuracy of the data analysis. ZX and ZS obtained funding. WL designed the research and drafted the manuscript. WD and LZ performed the statistical analysis. YD and LJ collected the images. ZS contributed to the acquisition and interpretation of the data. YL critically reviewed and revised the article for important intellectual content. All authors approved the final manuscript and decided to submit the article for publication.

Conflicts of Interest

None declared.

References

1. Wang Y, Ma J, Yin T, Han Z, Cui S, Liu Z, et al. Correlation Between Reduction Quality of Femoral Neck Fracture and Femoral Head Necrosis Based on Biomechanics. *Orthop Surg*. Apr 26, 2019;11(2):318-324. [FREE Full text] [doi: [10.1111/os.12458](https://doi.org/10.1111/os.12458)] [Medline: [31025811](https://pubmed.ncbi.nlm.nih.gov/31025811/)]
2. Florschütz AV, Langford JR, Haidukewych GJ, Koval KJ. Femoral Neck Fractures. *Journal of Orthopaedic Trauma*. Mar 2015;29(3):121-129. [doi: [10.1097/bot.0000000000000291](https://doi.org/10.1097/bot.0000000000000291)] [Medline: [25635363](https://pubmed.ncbi.nlm.nih.gov/25635363/)]
3. Makris UE, Abrams RC, Gurland B, Reid MC. Management of persistent pain in the older patient: a clinical review. *JAMA*. Aug 27, 2014;312(8):825-836. [FREE Full text] [doi: [10.1001/jama.2014.9405](https://doi.org/10.1001/jama.2014.9405)] [Medline: [25157726](https://pubmed.ncbi.nlm.nih.gov/25157726/)]
4. Kwoh Y, Hou J, Jonckheere E, Hayati S. A robot with improved absolute positioning accuracy for CT guided stereotactic brain surgery. *IEEE Trans Biomed Eng*. Feb 1988;35(2):153-160. [doi: [10.1109/10.1354](https://doi.org/10.1109/10.1354)] [Medline: [3280462](https://pubmed.ncbi.nlm.nih.gov/3280462/)]
5. Picard F, Deakin AH, Riches PE, Deep K, Baines J. Computer assisted orthopaedic surgery: Past, present and future. *Med Eng Phys*. Oct 2019;72:55-65. [doi: [10.1016/j.medengphy.2019.08.005](https://doi.org/10.1016/j.medengphy.2019.08.005)] [Medline: [31554577](https://pubmed.ncbi.nlm.nih.gov/31554577/)]
6. Ringel F, Stüer C, Reinke A, Preuss A, Behr M, Auer F, et al. Accuracy of Robot-Assisted Placement of Lumbar and Sacral Pedicle Screws. *Spine*. Apr 15, 2012;37(8):E496-E501. [doi: [10.1097/brs.0b013e31824b7767](https://doi.org/10.1097/brs.0b013e31824b7767)] [Medline: [22310097](https://pubmed.ncbi.nlm.nih.gov/22310097/)]
7. Vo CD, Jiang B, Azad TD, Crawford NR, Bydon A, Theodore N. Robotic Spine Surgery: Current State in Minimally Invasive Surgery. *Global Spine J*. Apr 28, 2020;10(2 Suppl):34S-40S. [FREE Full text] [doi: [10.1177/2192568219878131](https://doi.org/10.1177/2192568219878131)] [Medline: [32528804](https://pubmed.ncbi.nlm.nih.gov/32528804/)]
8. Schatlo B, Molliqaj G, Cuvinciuc V, Kotowski M, Schaller K, Tessitore E. Safety and accuracy of robot-assisted versus fluoroscopy-guided pedicle screw insertion for degenerative diseases of the lumbar spine: a matched cohort comparison. *SPI*. Jun 2014;20(6):636-643. [doi: [10.3171/2014.3.spine13714](https://doi.org/10.3171/2014.3.spine13714)] [Medline: [24725180](https://pubmed.ncbi.nlm.nih.gov/24725180/)]
9. Meng X, Guan X, Zhang H, He S. Computer navigation versus fluoroscopy-guided navigation for thoracic pedicle screw placement: a meta-analysis. *Neurosurg Rev*. Jul 19, 2016;39(3):385-391. [doi: [10.1007/s10143-015-0679-2](https://doi.org/10.1007/s10143-015-0679-2)] [Medline: [26686852](https://pubmed.ncbi.nlm.nih.gov/26686852/)]
10. Zeng T. Application of the Orthopedics Robot Navigation Positioning System in Assistance of Hollow Screw Internal Fixation for Femoral Neck Fractures. *China Medical Devices*. 2015;30(8):111-113. [doi: [10.3969/j.issn.1674-1633.2015.08.036](https://doi.org/10.3969/j.issn.1674-1633.2015.08.036)]
11. Wu J, Lu AD, Zhang LP, Zuo YX, Jia YP. [Study of clinical outcome and prognosis in pediatric core binding factor-acute myeloid leukemia]. *Zhonghua Xue Ye Xue Za Zhi*. Jan 14, 2019;40(1):52-57. [FREE Full text] [doi: [10.3760/cma.j.issn.0253-2727.2019.01.010](https://doi.org/10.3760/cma.j.issn.0253-2727.2019.01.010)] [Medline: [30704229](https://pubmed.ncbi.nlm.nih.gov/30704229/)]
12. Zielinski SM, Meeuwis MA, Heetveld MJ, Verhofstad MHJ, Roukema GR, Patka P, et al. Dutch femoral neck fracture investigator group. Adherence to a femoral neck fracture treatment guideline. *Int Orthop*. Jul 18, 2013;37(7):1327-1334. [FREE Full text] [doi: [10.1007/s00264-013-1888-3](https://doi.org/10.1007/s00264-013-1888-3)] [Medline: [23595233](https://pubmed.ncbi.nlm.nih.gov/23595233/)]
13. Weil YA, Qawasmi F, Liebergall M, Mosheiff R, Khoury A. Use of fully threaded cannulated screws decreases femoral neck shortening after fixation of femoral neck fractures. *Arch Orthop Trauma Surg*. May 9, 2018;138(5):661-667. [doi: [10.1007/s00402-018-2896-y](https://doi.org/10.1007/s00402-018-2896-y)] [Medline: [29427201](https://pubmed.ncbi.nlm.nih.gov/29427201/)]
14. Zielinski SM, Keijsers NL, Praet SF, Heetveld MJ, Bhandari M, Wilssens JP, et al. FAITH Trial Investigators. Femoral neck shortening after internal fixation of a femoral neck fracture. *Orthopedics*. Jul 01, 2013;36(7):e849-e858. [doi: [10.3928/01477447-20130624-13](https://doi.org/10.3928/01477447-20130624-13)] [Medline: [23823040](https://pubmed.ncbi.nlm.nih.gov/23823040/)]
15. Ly T, Swiontkowski M. Treatment of femoral neck fractures in young adults. *J Bone Joint Surg Am*. Oct 2008;90(10):2254-2266. [Medline: [18829925](https://pubmed.ncbi.nlm.nih.gov/18829925/)]
16. Hofstetter R, Slomczykowski M, Sati M, Nolte L. Fluoroscopy as an imaging means for computer - assisted surgical navigation. *Comput. Aided Surg*. 1999;4(2):65-76. [doi: [10.1002/\(sici\)1097-0150\(1999\)4:2<65::aid-igs1>3.3.co;2-p](https://doi.org/10.1002/(sici)1097-0150(1999)4:2<65::aid-igs1>3.3.co;2-p)] [Medline: [10494136](https://pubmed.ncbi.nlm.nih.gov/10494136/)]
17. Wolinsky PR, McCarty E, Shyr Y, Johnson K. Reamed intramedullary nailing of the femur: 551 cases. *J Trauma*. Mar 1999;46(3):392-399. [doi: [10.1097/00005373-199903000-00007](https://doi.org/10.1097/00005373-199903000-00007)] [Medline: [10088839](https://pubmed.ncbi.nlm.nih.gov/10088839/)]
18. Ju DG, Rajae SS, Mirocha J, Lin CA, Moon CN. Nationwide Analysis of Femoral Neck Fractures in Elderly Patients. *The Journal of Bone and Joint Surgery*. 2017;99(22):1932-1940. [doi: [10.2106/jbjs.16.01247](https://doi.org/10.2106/jbjs.16.01247)] [Medline: [29135667](https://pubmed.ncbi.nlm.nih.gov/29135667/)]
19. Karthik K, Colegate-Stone T, Dasgupta P, Tavakkolizadeh A, Sinha J. Robotic surgery in trauma and orthopaedics: a systematic review. *Bone Joint J*. Mar 2015;97-B(3):292-299. [doi: [10.1302/0301-620X.97B3.35107](https://doi.org/10.1302/0301-620X.97B3.35107)] [Medline: [25737510](https://pubmed.ncbi.nlm.nih.gov/25737510/)]
20. Leonardsson O, Sernbo I, Carlsson A, Akesson K, Rogmark C. Long-term follow-up of replacement compared with internal fixation for displaced femoral neck fractures: results at ten years in a randomised study of 450 patients. *J Bone Joint Surg Br*. Mar 2010;92(3):406-412. [doi: [10.1302/0301-620X.92B3.23036](https://doi.org/10.1302/0301-620X.92B3.23036)] [Medline: [20190313](https://pubmed.ncbi.nlm.nih.gov/20190313/)]
21. Mei J, Liu S, Jia G, Cui X, Jiang C, Ou Y. Finite element analysis of the effect of cannulated screw placement and drilling frequency on femoral neck fracture fixation. *Injury*. Dec 2014;45(12):2045-2050. [doi: [10.1016/j.injury.2014.07.014](https://doi.org/10.1016/j.injury.2014.07.014)] [Medline: [25172530](https://pubmed.ncbi.nlm.nih.gov/25172530/)]

22. Hamelinck HKM, Haagsmans M, Snoeren MM, Biert J, van Vugt AB, Frölke JPM. Safety of computer-assisted surgery for cannulated hip screws. *Clin Orthop Relat Res*. Feb 2007;455:241-245. [doi: [10.1097/01.bl.0000238815.40777.d2](https://doi.org/10.1097/01.bl.0000238815.40777.d2)] [Medline: [16957645](https://pubmed.ncbi.nlm.nih.gov/16957645/)]
23. Yuenyongviwat V, Tuntarattanapong P, Tangtrakulwanich B. A new adjustable parallel drill guide for internal fixation of femoral neck fracture: a developmental and experimental study. *BMC Musculoskelet Disord*. Jan 11, 2016;17(1):8. [FREE Full text] [doi: [10.1186/s12891-015-0845-2](https://doi.org/10.1186/s12891-015-0845-2)] [Medline: [26754287](https://pubmed.ncbi.nlm.nih.gov/26754287/)]
24. Kumar MN, Belehalli P, Ramachandra P. PET/CT study of temporal variations in blood flow to the femoral head following low-energy fracture of the femoral neck. *Orthopedics*. Jun 01, 2014;37(6):e563-e570. [doi: [10.3928/01477447-20140528-57](https://doi.org/10.3928/01477447-20140528-57)] [Medline: [24972438](https://pubmed.ncbi.nlm.nih.gov/24972438/)]

Abbreviations

CT: computed tomography

Edited by G Eysenbach; submitted 07.Sep.2020; peer-reviewed by Z Chen, J Li; comments to author 24.Sep.2020; revised version received 10.Nov.2020; accepted 12.Dec.2020; published 21.Jan.2021

Please cite as:

Wan L, Zhang X, Wu D, Li Z, Yuan D, Li J, Zhang S, Yue L, Zhang S

Retracted: Application of Robot Positioning for Cannulated Screw Internal Fixation in the Treatment of Femoral Neck Fracture: Retrospective Study

JMIR Med Inform 2021;9(1):e24164

URL: <http://medinform.jmir.org/2021/1/e24164/>

doi: [10.2196/24164](https://doi.org/10.2196/24164)

PMID: [33475515](https://pubmed.ncbi.nlm.nih.gov/33475515/)

©Lei Wan, Xiangyun Zhang, Dalong Wu, Zhihao Li, Dongtao Yuan, Junming Li, Shikui Zhang, Long Yue, Shao'an Zhang. Originally published in JMIR Medical Informatics (<http://medinform.jmir.org>), 21.Jan.2021. This is an open-access article distributed under the terms of the Creative Commons Attribution License (<https://creativecommons.org/licenses/by/4.0/>), which permits unrestricted use, distribution, and reproduction in any medium, provided the original work, first published in JMIR Medical Informatics, is properly cited. The complete bibliographic information, a link to the original publication on <http://medinform.jmir.org/>, as well as this copyright and license information must be included.